

# Do partial rotator cuff tears cause humeral migration?

Emre Arıkan<sup>1</sup>, Tacettin Ayanođlu<sup>2</sup>, Oya Kalaycıođlu<sup>3</sup>, Ömer Faruk Yılmaz<sup>2</sup>,  
Mahmut Timur Turhan<sup>2</sup>, İlhan Çelik<sup>4</sup>, Hüsamettin Çakıcı<sup>2</sup>

<sup>1</sup>Department of Orthopaedics and Traumatology, Bursa Yuksek İhtisas Training and Research Hospital, Bursa, Türkiye

<sup>2</sup>Department of Orthopaedics and Traumatology, Bolu Abant İzzet Baysal University, Bolu, Türkiye

<sup>3</sup>Department of Biostatistics, Bolu Abant İzzet Baysal University, Bolu, Türkiye

<sup>4</sup>Department of Orthopaedics and Traumatology, Alanya Alaaddin Keykubat University Training and Research Hospital, Antalya, Türkiye

**Cite as:** Arıkan E, Ayanođlu T, Kalaycıođlu O, et al. Do partial rotator cuff tears cause humeral migration?. Northwestern Med J. 2024;4(3):127-133.

## ABSTRACT

**Aim:** This study aims to analyze the effect of symptomatic partial and full-thickness rotator cuff tears on humeral migration. The hypothesis of the study was that superior humeral migration varies according to the type of rotator cuff tear.

**Methods:** 80 patients who underwent arthroscopic repair between 2017 and 2021 were retrospectively evaluated. Humerus migration directions and distances of patients in the isolated Bankart lesion (Group 1), bursal-side partial (Group 2), articular-side partial (Group 3), and full-thickness rotator cuff tear (Group 4) groups whose diagnosis was confirmed by shoulder arthroscopic intervention MRI were recorded and evaluated.

**Results:** There was no significant difference between the groups according to age ( $p=0.295$ ). Migration distance values of isolated Bankart lesions (Group 1) were significantly lower in men ( $p<0.005$ ). While superior migration rates were significantly increased in full-thickness tears, they were similar in partial tears ( $p<0.005$ ). The mean migration distance was similar between groups ( $p=0.153$ ).

**Conclusion:** Symptomatic full-thickness rotator cuff tears lead to humeral migration. Superior humeral migration was not found to be significant in partial rotator cuff tears, regardless of bursal or articular.

**Keywords:** humeral migration, MRI, rotator cuff, shoulder

**Corresponding author:** Emre Arıkan **E-mail:** dremrearikan@gmail.com

**Received:** 06.05.2023 **Accepted:** 11.12.2023 **Published:** 12.07.2024

Copyright © 2024 The Author(s). This is an open-access article published by Bolu İzzet Baysal Training and Research Hospital under the terms of the [Creative Commons Attribution License \(CC BY\)](#) which permits unrestricted use, distribution, and reproduction in any medium or format, provided the original work is properly cited.

## INTRODUCTION

There is no consensus among authors who study humeral head migration as to which types of rotator cuff tears cause humeral migration.

There are two types of rotator cuff tears: full-thickness tears and partial tears. Bursal side and articular side tears are two different types of partial tears based on where they are located (1). Rotator cuff tears are more common as people age and are generally brought on by two mechanisms: intrinsic and extrinsic. According to Codman and Matsen, extrinsic factors are caused by subacromial impingement syndrome, while intrinsic factors are caused by degenerative changes (2,3). We also know that non-traumatic tears start as partial tears and then return to full-thickness over time, and then migration develops. However, we know that partial tears occur in different etiologies (4).

Rotator cuff tears impair normal glenohumeral biomechanics and also narrow the acromiohumeral space (5,6). According to Weiner et al., supraspinatus tears were the primary cause of the superior humeral head displacement (7). The humeral head shifts superiorly on the glenoid as a result of rotator cuff damage, changing the biomechanics of the glenohumeral joint (8,9). Subscapularis tendon tears do not cause migration of the superior humerus. Even when the subscapularis tendon is intact, rotator cuff injuries can still result in superior humeral migration and subacromial impingement (10). Rotator cuff injury may result in dynamic anterosuperior instability with loss of the coracoacromial arch and anterior deltoid, abduction, or flexion of the shoulder (11). Acromiohumeral distance is considered an important measure of humeral head elevation (12). Hamada and coworkers diagnosed radiographically significant rotator cuff injuries using this scale and recommended rotator cuff restoration before the acromiohumeral space narrows (13,14).

We sought to understand how the type of rotator cuff tear affects the humeral migration in both direction and distance in this study, as well as whether partial tears contribute to migration. The hypothesis of the study was that superior humeral migration varies according to the type of rotator cuff injury.

## PATIENTS AND METHODS

Retrospective analysis was performed on the reported data of patients who underwent shoulder arthroscopy between 2017 and 2021. Ethical approval was obtained from Bolu Abant İzzet Baysal University Clinical Research Ethics Committee (2021/51) for this retrospective study. Patients with compatible MRI and intraoperative findings were selected for the study. In order to support the diagnostic accuracy, there is a period of less than 1 month between the MRI scan times and the time of surgery. Approximately 80 patients, regardless of gender, were included in the study. The isolated Bankart lesion group was included in Group 1, the bursal-side partial supraspinatus injury in Group 2, the articular-side partial supraspinatus injury in Group 3, and the full-thickness supraspinatus injury in Group 4.

After evaluating whether it was normally and homogeneously distributed, humeral migration was found to be suitable for analysis with parametric tests as a continuous variable. The patients included in the study were selected and divided into groups with the help of online software called Research Randomizer Version 4.0 (2015, Geoffrey C. Urbaniak and Scott Plous). The median gender, age, and humeral migration distance and direction of the patients were recorded. Humeral migration distance was measured in the MRI coronal section using RadiAnt application, based on the humeral head center and glenoid center.

Exclusion criteria included patients with a history of surgery, a history of trauma near the shoulders on the same side, and patients diagnosed with osteoarthritis, previous infection, autoimmune joint disease, hemophilic arthritis, and pyrophosphate disease.

The categorization of rotator cuff tears was carried out by a senior surgeon with ten years of experience in shoulder arthroscopy and two junior physicians employed by the same hospital. All surgeries were carried out under general anesthesia. The patients were allowed a 20 degrees of posterior displacement during the procedures since they were performed in the lateral decubitus posture, parallel to the glenoid fossa floor. Under 70 N of longitudinal tension, the arm was stabilized in a posture of 15 degrees of forward flexion

and 45 degrees of abduction. After the necessary cleaning and draping, diagnosis and treatment were performed using a 30-degree angle arthroscope and posterior viewing portal.

### MR imaging assessment

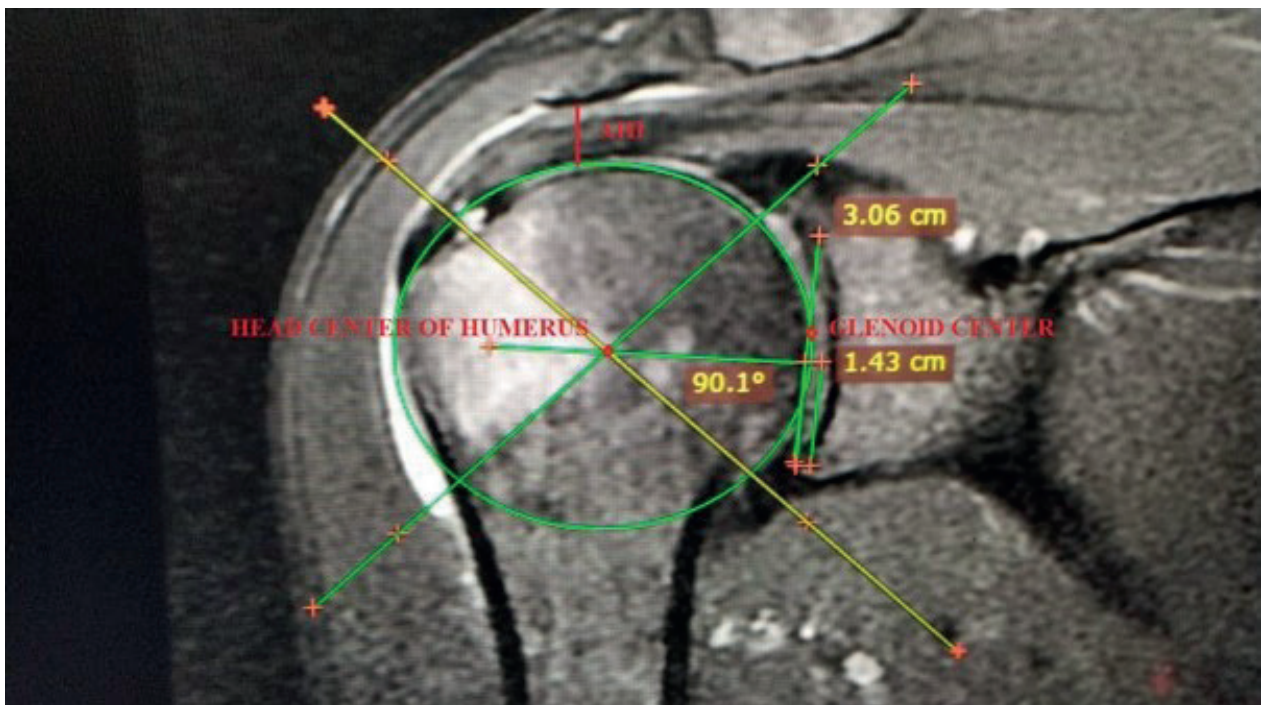
MR examinations were performed with a special shoulder coil on the 1.5 T system (Siemens Magnetom Symphony, Erlangen, Germany) in the supine position with the patient's arm lying on the side of the body in neutral rotation. Imaging protocol oblique coronal T1-weighted (TR/TE:600/16) and fat-suppressed intermediate (T2-weighted (TR/TE:3000/56)), oblique coronal T1-weighted [TR/TE:500/ 16] and fat-suppressed intermediate (TR/TE:3000/56) and T2-weighted axial (TR/TE:500/15, rotation angle:30) images, field of view 18 cm in all sequences, matrix 192x384 256 and slice thickness/slice spacing 3e4/ 0e1 mm was.

### Statistical analysis

In descriptive statistics, numerical variables were provided as mean, standard deviation, median, and

minimum and maximum values, while categorical variables are given as number and percentage values. For statistical analysis, results are presented as mean  $\pm$  SD. Age distributions were compared using the Student t-test. The Pearson chi-squared test was used to determine whether there was a meaningful correlation between categorical variables. To determine if the means of two or more samples varied from one another, the Kruskal Wallis test was utilized. The statistical significance of the difference between the means of independent groups was examined using the ANOVA test. The threshold for significance was defined as  $p < 0.05$ . SPSS for Windows 24.0 (Chicago, IL, USA) was used for all statistical analyses.

The two authors of this study assessed and measured the MRI scans in collaboration with a professorial radiologist specialized in musculoskeletal imaging. The clinical and arthroscopic information of the patients was hidden from these two observers. Humeral migration measures were modified for MRI based on a previous radiographic description (13-15). In this technique, the center of the humeral head was identified by drawing a circle fitting the humeral head.



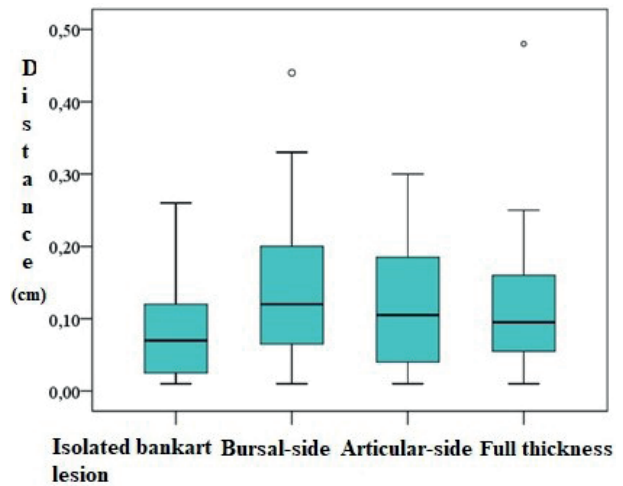
**Figure 1.** Humerus migration distance values.

The center of the glenoid cavity was identified by drawing two perpendicular reference lines intersecting at the humeral head center (one vertical and one horizontal). Finally, the vertical distance from the humeral head center to a horizontal line through the glenoid center was measured as the superior migration (Figure 1). The humeral migration was measured as a positive or negative number, depending on whether the humeral head was superior to or inferior to the central junction point.

## RESULTS

The groups' demographic and clinical traits were comparable ( $p > 0.05$  for all) (Table 1). Group 1 had a lower mean age ( $46.6 \pm 6.8$ ) than the other 3 groups. The oldest group of patients ( $50.2 \pm 5.8$ ) had a partial rotator cuff injury on the articular side. Age distribution was similar in all groups ( $p = 0.295$ ). Female gender was most frequent among patients with articular side partial rotator cuff injury (80%). Data from 80 patients were analyzed.

In comparison to the intact group, the migration distance was greater in the groups with bursal, articular, and full-thickness rotator cuff tears ( $p > 0.05$ , Figure 2). According to gender, the superior migration distance values of the intact male group were lower than the



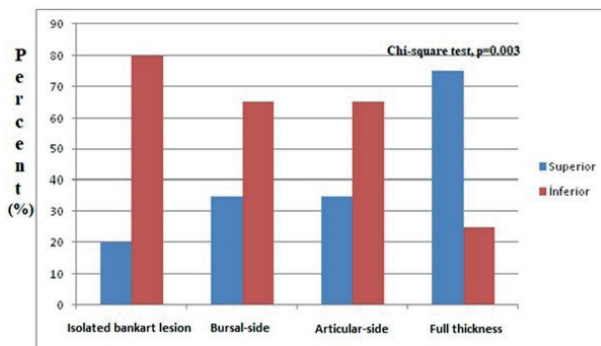
**Figure 2.** Humerus migration distance measurement.

other groups ( $p < 0.005$ ). However, in women, the distance values of patients in the Bankart lesion group were higher. While the rate of superior migration was significantly higher (75%) in full-thickness tears, it was similar in patients with partial tears (35%) ( $p < 0.005$ ) (Figure 3). The mean migration distance was 0.07 (0.02-0.12) cm in Group 1, 0.12 (0.06-0.20) cm in Group 2, 0.11 (0.04-0.19) cm in Group 3, and 0.10 (0.05-0.16) cm in Group 4. There was no discernible distinction between the groups ( $p = 0.153$ , Table 1).

**Table 1.** Demographic information and migration measurements (p value)

|                   | Isolated bankart lesion (n=20) | Bursal-side (n=20) | Articular-side (n=20) | Full Thickness (n=20) | p                        |
|-------------------|--------------------------------|--------------------|-----------------------|-----------------------|--------------------------|
| Age, year         | 46.6±6.8                       | 49.3±5.8           | 50.2±5.8              | 48.3±6.5              | 0.295 <sup>a</sup>       |
| Gender            |                                |                    |                       |                       | <b>0.016<sup>b</sup></b> |
| Female            | 6 (%30)                        | 11 (%55)           | 16 (%80)              | 12 (%60)              |                          |
| Male              | 14 (%70)                       | 9 (%45)            | 4 (%20)               | 8 (%40)               |                          |
| Superior/Inferior |                                |                    |                       |                       | <b>0.003<sup>b</sup></b> |
| Superior          | 4 (%20)                        | 7 (%35)            | 7 (%35)               | 15 (%75)              |                          |
| Inferior          | 16 (%80)                       | 13 (%65)           | 13 (%65)              | 5 (%25)               |                          |
| Distance, cm      | 0.07 (0.02-0.12)               | 0.12 (0.06-0.20)   | 0.11 (0.04-0.19)      | 0.10 (0.05-0.16)      | 0.153 <sup>c</sup>       |

Numerical data were summarized as mean±standard deviation or median (1st-3rd quartile), and categorical data were summarized as numbers (percentage). <sup>a</sup>One-way ANOVA, <sup>b</sup>Pearson's chi-square test, <sup>c</sup>Kruskal-Wallis test



**Figure 3.** Humerus migration values according to rotator cuff tear types.

## DISCUSSION

The study's key conclusion is that superior humeral migration is not brought on by partial rotator cuff injuries. Full-thickness supraspinatus tears are linked to superior humeral migration, which is consistent with the literature. In terms of gender, the migration distance values of the intact group of males were significantly lower than the other groups.

Sharkey and Marder revealed that the stability of the glenohumeral joint is influenced by all of the rotator cuffs parts in a cadaver research (5). There are many studies on superior migration of the proximal humerus, and it is seen with advanced rotator cuff tears (6,16-18). The rotator cuff supplies the deltoids pulling power, which tends to detach the humeral head from the glenoid, and fixes the humeral head in the glenoid to cause elevation (19). If the rotator cuff mechanism is defective, there is no force to resist the deltoid and migration occurs.

Patients with isolated supraspinatus tears and patients with supraspinatus and infraspinatus tears did not significantly differ in their humeral head elevation, according to our research. However, individuals with supraspinatus, infraspinatus, and subscapularis tears had a statistically significant increase in the superior displacement of the humeral head above the glenoid (6).

A limit value for migration was determined according to the tear site in symptomatic shoulders. Tears with an area of 175 mm<sup>2</sup> cause more migration than smaller tears (15). Contrary to prior research, Cetinkaya et al. discovered that isolated supraspinatus tears may allow superior humerus migration even in the presence of an intact subscapularis (10).

Siow et al. suggest that infraspinatus tears are associated with the smallest acromiohumeral distance among all rotator cuff tendons. Massive infraspinatus tears were linked to the biggest reduction in acromiohumeral distance (>3 mm) (20). Additionally, compared to isolated supraspinatus tears or a combination of tears, isolated infraspinatus tears were linked to a smaller mean acromiohumeral distance (20). Superior rotator cuff injuries and therefore an undamaged subscapularis tendon do not prevent superior humeral migration and subacromial impingement produced by a superior rotator cuff tear, but subscapularis tears do not induce superior humeral migration and subacromial compression (10).

On radiography and MRI, individuals treated with partial repair exhibited considerably smaller acromiohumeral spaces and higher upward migration indices than patients with totally repairable tears (21). Our study was compatible with the literature on this subject.

Orthopedic surgeons utilizing non-standard radiographs to assess the acromiohumeral space were shown by Bernhardt et al. to be neither trustworthy nor repeatable (22). Gravity can affect this comparison since MR images are captured in the supine position, but X-ray images are taken in standing and upright position (23). As a result, in our research, we exclusively employed supine MR images of the shoulder. In our practice, these techniques are regularly applied to the preoperative assessment of rotator cuff injuries. For this reason, in our study, both the effect of gravity was eliminated by using MRI and standardization was achieved by using the same position during MRI.

In the Park et al. research, both genders had the same ratio of partial or full-thickness rotator cuff injuries (21). Women are more likely than males to need dominant arm surgery, and their rotator cuff injuries are often smaller (24). According to the study by Lapner et al., when the Upward migration index (UMI) is examined, low UMI is more frequent in males, while high UMI is more frequent in females (25). Decreased UMI is a predictable and reliable sign of rotator cuff tear and degeneration in the clinic (26). In our study, the migration distance values of the healthy group of males were significantly lower than the other groups when grouped by gender ( $p < 0.005$ ).

As a result, there are many studies in the literature on total ruptures of the infraspinatus, subscapularis, and supraspinatus muscles, which are among the muscles forming the rotator cuff, and the contribution of these muscles to the migration of the acromiohumeral distance. In our study, we evaluated supraspinatus muscle tears as bursal side partial, articular side partial, and full-thickness supraspinatus tears. We demonstrated that partial rotator cuff tears do not affect migration. We reported that full-thickness supraspinatus tears are linked to superior humeral migration, which is consistent with the literature.

### Limitations

This study's primary flaw is the lack of MRI comparisons at different active elevation angles. With vigorous abduction, the degree of humeral migration may change. Another significant restriction is the lack of radiological information on the shoulder on the other side. Additionally, the interval between the onset of symptoms and operation was not tracked. An additional limitation was the low number of patients in the groups. Another limitation is the lack of rotator cable integrity evaluation.

Superior humeral migration is caused by symptoms of full-thickness rotator cuff rupture. However, superior humeral migration distances differ significantly according to gender. In partial rotator cuff tears, superior humeral migration is not observed regardless of the location.

### Ethical approval

This study has been approved by the Bolu Abant İzzet Baysal University Clinical Research Ethics Committee (approval date 27.04.2021, number 2021/51). Written informed consent was obtained from the participants.

### Author contribution

Concept: EA, TA, İÇ, HÇ; Design: EA, OK, İÇ; Data Collection or Processing: EA, ÖFY, MTT; Analysis or Interpretation: EA, OK; Literature Search: EA, ÖFY, TA; Writing: EA, TA, HÇ. All authors reviewed the results and approved the final version of the article.

### Source of funding

The authors declare the study received no funding.

### Conflict of interest

The authors declare that there is no conflict of interest.

## REFERENCES

1. Smith TO, Daniell H, Geere JA, Toms AP, Hing CB. The diagnostic accuracy of MRI for the detection of partial- and full-thickness rotator cuff tears in adults. *Magn Reson Imaging*. 2012; 30(3): 336-46. [\[Crossref\]](#)
2. Seitz AL, McClure PW, Finucane S, Boardman ND, Michener LA. Mechanisms of rotator cuff tendinopathy: intrinsic, extrinsic, or both? *Clin Biomech (Bristol, Avon)*. 2011; 26(1): 1-12. [\[Crossref\]](#)
3. Codman EA, Peltier LF. The Classic: Rupture of the supraspinatus tendon. *Clin Orthop Relat Res*. 1990; 254: 3-26. [\[Crossref\]](#)
4. Löhr JF, Uhthoff HK. Epidemiology and pathophysiology of rotator cuff tears. *Orthopade*. 2007; 36(9): 788-95. [\[Crossref\]](#)
5. Sharkey NA, Marder RA. The rotator cuff opposes superior translation of the humeral head. *Am J Sports Med*. 1995; 23(3): 270-5. [\[Crossref\]](#)
6. Bezer M, Yildirim Y, Akgün U, Erol B, Güven O. Superior excursion of the humeral head: a diagnostic tool in rotator cuff tear surgery. *J Shoulder Elbow Surg*. 2005; 14(4): 375-9. [\[Crossref\]](#)
7. Weiner DS, Macnab I. Superior migration of the humeral head. A radiological aid in the diagnosis of tears of the rotator cuff. *J Bone Joint Surg Br*. 1970; 52(3): 524-7. [\[Crossref\]](#)
8. Nam D, Maak TG, Raphael BS, Kepler CK, Cross MB, Warren RF. Rotator cuff tear arthropathy: evaluation, diagnosis, and treatment: AAOS exhibit selection. *J Bone Joint Surg Am*. 2012; 94(6): e34. [\[Crossref\]](#)

9. Abrams JS, Song FS. Arthroscopic repair techniques for massive rotator cuff tears. *Instr Course Lect.* 2012; 61: 121-30.
10. Cetinkaya M, Ataoglu MB, Ozer M, Ayanoglu T, Oner AY, Kanatli U. Do subscapularis tears really result in superior humeral migration? *Acta Orthop Traumatol Turc.* 2018; 52(2): 109-14. [[Crossref](#)]
11. Galatz LM, Connor PM, Calfee RP, Hsu JC, Yamaguchi K. Pectoralis major transfer for anterior-superior subluxation in massive rotator cuff insufficiency. *J Shoulder Elbow Surg.* 2003; 12(1): 1-5. [[Crossref](#)]
12. Ellman H, Hanker G, Bayer M. Repair of the rotator cuff. End-result study of factors influencing reconstruction. *J Bone Joint Surg Am.* 1986; 68(8): 1136-44. [[Crossref](#)]
13. Hamada K, Fukuda H, Mikasa M, Kobayashi Y. Roentgenographic findings in massive rotator cuff tears. A long-term observation. *Clin Orthop Relat Res.* 1990; 254: 92-6. [[Crossref](#)]
14. Hamada K, Yamanaka K, Uchiyama Y, Mikasa T, Mikasa M. A radiographic classification of massive rotator cuff tear arthritis. *Clin Orthop Relat Res.* 2011; 469(9): 2452-60. [[Crossref](#)]
15. Keener JD, Wei AS, Kim HM, Steger-May K, Yamaguchi K. Proximal humeral migration in shoulders with symptomatic and asymptomatic rotator cuff tears. *J Bone Joint Surg Am.* 2009; 91(6): 1405-13. [[Crossref](#)]
16. Saupé N, Pfirrmann CW, Schmid MR, Jost B, Werner CM, Zanetti M. Association between rotator cuff abnormalities and reduced acromiohumeral distance. *AJR Am J Roentgenol.* 2006; 187(2): 376-82. [[Crossref](#)]
17. Norwood LA, Barrack R, Jacobson KE. Clinical presentation of complete tears of the rotator cuff. *J Bone Joint Surg Am.* 1989; 71(4): 499-505.
18. Kim SJ, Park JS, Lee KH, Lee BG. The development of a quantitative scoring system to predict whether a large-to-massive rotator cuff tear can be arthroscopically repaired. *Bone Joint J.* 2016; 98-B(12): 1656-61. [[Crossref](#)]
19. Bechtol CO. Biomechanics of the shoulder. *Clin Orthop Relat Res.* 1980; 146: 37-41. [[Crossref](#)]
20. Siow MY, Mitchell BC, Hachadorian M, et al. Association Between Rotator Cuff Tears and Superior Migration of the Humeral Head: An MRI-Based Anatomic Study. *Orthop J Sports Med.* 2021; 9(6): 23259671211009846. [[Crossref](#)]
21. Park SH, Choi CH, Yoon HK, Ha JW, Lee C, Chung K. What can the radiological parameters of superior migration of the humeral head tell us about the reparability of massive rotator cuff tears? *PLoS One.* 2020; 15(4): e0231843. [[Crossref](#)]
22. Bernhardt GA, Glehr M, Zacherl M, Wurnig C, Gruber G. Observer variability in the assessment of the acromiohumeral interval using anteroposterior shoulder radiographs. *Eur J Orthop Surg Traumatol.* 2013; 23(2): 185-90. [[Crossref](#)]
23. Werner CM, Conrad SJ, Meyer DC, Keller A, Hodler J, Gerber C. Intermethod agreement and interobserver correlation of radiologic acromiohumeral distance measurements. *J Shoulder Elbow Surg.* 2008; 17(2): 237-40. [[Crossref](#)]
24. Sabo MT, LeBlanc J, Hildebrand KA. Patient gender and rotator cuff surgery: are there differences in outcome? *BMC Musculoskelet Disord.* 2021; 22(1): 838. [[Crossref](#)]
25. Lapner PC, Su Y, Simon D, El-Fatori S, Lopez-Vidriero E. Does the upward migration index predict function and quality of life in arthroscopic rotator cuff repair? *Clin Orthop Relat Res.* 2010; 468(11): 3063-9. [[Crossref](#)]
26. Zhang YC, Chen JH, Dang Y, et al. Correlation analysis between rotator cuff tear and the superior migration of humeral head. *Beijing Da Xue Xue Bao Yi Xue Ban.* 2019; 51(2): 273-6. [[Crossref](#)]